

CASE REPORT

S. Janssens · P. J. Govaerts · J. Casselman
 W. Van Rompaey · A. Van Langenhove · T. Somers
 F. E. Offeciers

The LAURA multichannel cochlear implant in a true Mondini dysplasia

Received: 20 June 1995 / Accepted: 19 September 1995

Abstract A congenitally deaf child with bilateral Mondini dysplasias of the inner ear was successfully implanted with a LAURA multichannel cochlear prosthesis. This is the first report of a patient with a Mondini dysplasia in whom a LAURA multichannel cochlear prosthesis was successfully implanted. The cerebrospinal fluid leakage typically occurring after cochleostomy in similar patients was readily controlled, indicating that the deformity present was not a contra-indication for cochlear surgery. The audiological results obtained are described in detail. Since the internal unit of the LAURA prosthesis is very flexible, various speech processing strategies, such as continuous interleaved and phase-locked continuous interleaved strategies, can be tried and evaluated.

Key words Sensorineural hearing loss · Congenital cochlear diseases · Mondini dysplasia · Perilymph gusher · Cochlear implant

Introduction

The Mondini dysplasia is a congenital malformation of the inner ear that is characterized by a normal basal turn communicating with a distal sac. The middle and apical windings are missing [8]. The dysplasia seen can be associated with other diseases, such as Pendred syndrome, anencephaly, brancho-oto-renal dysplasia, Klippel-Feil

syndrome, trisomy and Di George's syndrome, but it may also occur as an isolated finding [4, 11]. In general, affected patients have severe sensorineural hearing losses, but some patients may present with minimal hearing impairments.

True Mondini dysplasia is believed to arise from an arrest of inner ear embryogenesis during the 7th week of gestation [1]. This causes an incomplete partition of the developing cochlea, which subsequently forms one and a half turns instead of two and three fourths.

Profound hearing loss in patients with Mondini dysplasia justifies cochlear implantation. However, this indication is controversial because of a continuing conviction that Mondini dysplasia bears a great risk for cerebrospinal fluid (CSF) leakage and recurrent meningitis.

There has been much confusion about the term "Mondini dysplasia," as virtually all congenital malformations of the bony labyrinth have occasionally been mislabeled as such. This terminology is mainly due to a lack of reliable classification of congenital inner ear deformities. Jackler et al. [1] and Phelps [9] have suggested a better differentiated classification, in which true Mondini dysplasia can be better distinguished from more severe inner ear malformations. These latter deformities bear a much greater risk for complications when compared to a true Mondini malformation [8, 10]. Based on radiological classification, it is now possible to implant the majority of congenital inner ear malformations and more objectively assess potential risks [2, 3, 9, 12].

Successful implantation of multichannel cochlear prostheses in a patient with Mondini dysplasia has been reported only by Silverstein et al. [12]. A number of other cases have been presented at international conferences, but to our knowledge have not been published. This paper is the first to report a LAURA multichannel cochlear implantation in a patient with a congenital inner ear malformation. This latter implant is known to be highly flexible regarding stimulation modalities [6], validating its utility in cases such as ours.

Case report

A 12-year-old girl with profound congenital bilateral deafness presented to our department for consideration of cochlear implanta-

P. J. Govaerts (✉) · S. Janssens · T. Somers · F. E. Offeciers
 University ENT Department, Sint-Augustinus Hospital,
 Oosterveldlaan 24, B-2610 Antwerp-Wilrijk, Belgium

J. Casselman
 Department of Medical Imaging, Sint-Jan Hospital,
 Bruges, Belgium

W. Van Rompaey
 Department of Medical Imaging, Sint-Augustinus Hospital,
 Antwerp, Belgium

A. Van Langenhove
 Department of Medical Electronics and Experimental ENT,
 University of Antwerp (UIA), Antwerp, Belgium

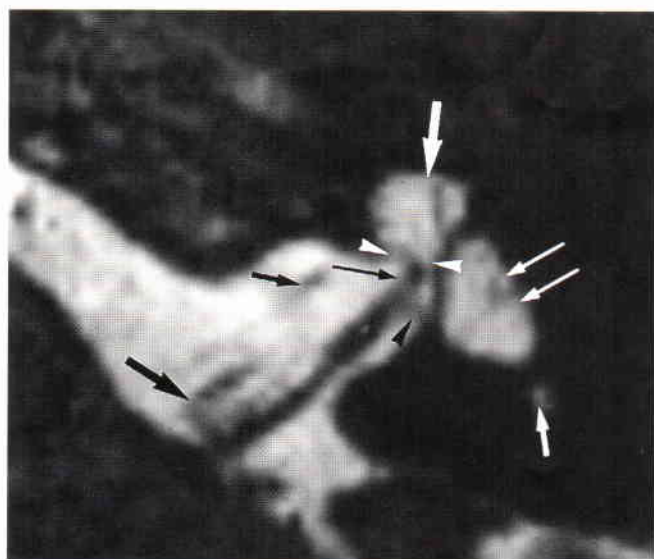


Fig. 4 Axial 0.7-mm-thick 3DFT-CISS MR images made at the level of the inferior part of the internal auditory canal. The cochlea has no second or apical turns and the modiolus is absent, making the cochlea appear as a cystic fluid-filled structure (*large white arrow*). The enlarged vestibule is again seen (*long white arrows*) and a broad connection between the abnormal cochlea and the broad fundus of the internal auditory canal is visible (*white arrowheads*). These findings indicate a potential “gusher ear.” The cochlear branch (*long black arrow*) and inferior vestibular branch of the vestibulocochlear nerve (*black arrowhead*) are visible on this image. Also seen are the facial nerve (*large black arrow*), vascular loop in the internal auditory canal (*small black arrow*) and posterior semicircular canal (*small white arrow*)

testing was undertaken at 3 months post-fitting and was conducted at a most comfortable loudness level of 70 dB SPL. Tests on three perception levels were performed (Fig. 5).

Performances on everyday sound signals (4-choice test) improved from zero to 67% (8/12). Good performance on a suprasegmental level was determined by the 3-choice “number of syllables” test (80% correct) as well as the 4-choice “number of words in a sentence” test (95% correct). There was still poor performance on the 3-choice voice recognition test (40% correct).

At a segmental level, monosyllabic word 4-choice identification improved from zero to 50% and 4-choice spondee testing improved from zero to 60%. Closed-set identification of 12 words representing stress pattern categories increased from 17% to 37% pure word score, while the prosodic score remained at 50%. Closed-set 4-choice testing of sentences increased from zero to 50%.

Auditory rehabilitation started with basic sound and speech awareness, followed by selective attention to specific sounds and speech. Training of suprasegmental cues comprised different prosodic features of speech, including rhythm, duration, accentuation and intonation, followed by segmental cues based on phonemes, syllables, words and sentences.

By training auditory memory the opportunity was given to the patient to enlarge closed sets of phonetic interpretation and to make the identification exercises more difficult. The patient also learned to connect auditory speech perception skills with speech-reading information and to integrate this multisensory information into different efficient conversation strategies.

At present audiological training is being continued both at school and at home. Long-term goals include increasing the patient’s communication skills such as speech-reading, monitoring her own voice, sharpening her ability to discriminate similar auditory stimuli and consistently being alert to meaningful sounds and speech. All clinicians involved in our patient’s care have noticed

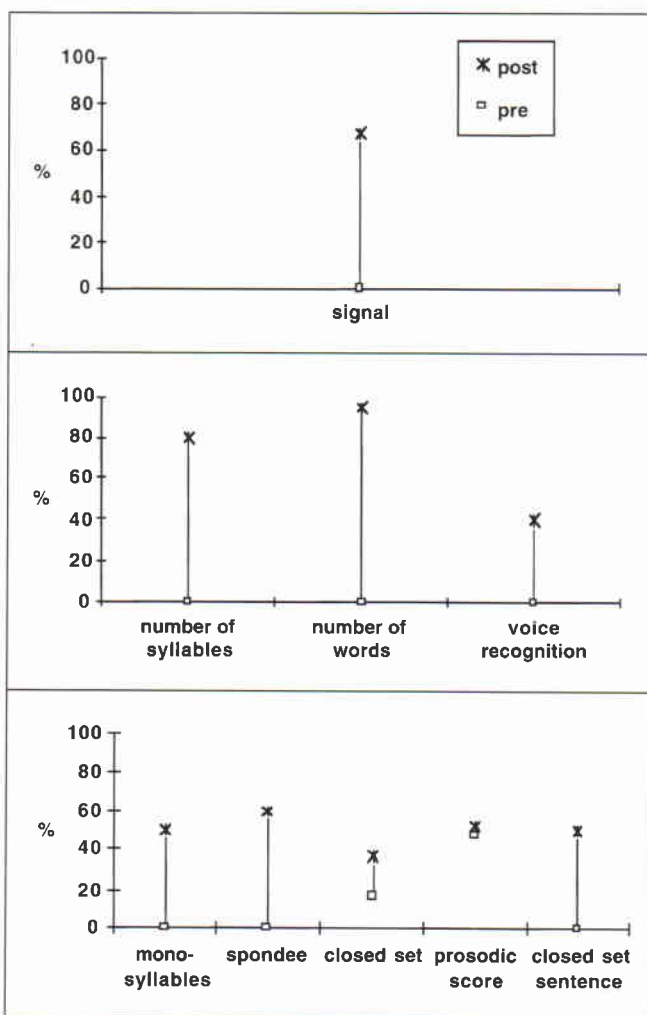


Fig. 5 Patient’s results of pre- and 3 months postoperative auditory tests on three perception levels: **A** signals, **B** suprasegmental, **C** segmental. See text for detailed comments. The preoperative suprasegmental cues are not available, since these tests are not routinely performed on children at the Sint-Augustinus Hospital

better oral communication as a result of significant progress in speech-reading and improved voice and speech quality after implantation. Academically, these improvements have turned our patient into a capable student in an oral class setting.

Discussion

Successful implantation of patients with true Mondini dysplasia has been reported in the recent literature [2, 3, 11, 12]. According to some authors, pseudo-Mondini dysplasias and other more severe malformations of the inner ear are not candidates for cochlear implantation because of the greater risk for accidental penetration of the electrode through the fundus into the internal auditory canal, especially in cases with an enlarged basal turn and minimal bony separation from the internal auditory canal. Extension of the subarachnoid space into the middle ear in-